

# Early Cytokine Removal in Critical COVID-19 Patients with Extracorporeal Therapies (HA-380 plus High Volume Hemofiltration) May Prevent Progression of Acute Respiratory Distress Syndrome: Case Report

Gonzalo Ramírez-Guerrero<sup>a, b</sup> Vicente Torres Cifuentes<sup>a, b</sup>  
Romyna Baghetti Hernández<sup>a</sup> Francisco Villagrán Cortés<sup>a, b</sup>  
Simón Rojas Doll<sup>a</sup> Rocio Oliva Alarcón<sup>a</sup> Cristian Lucero Córdova<sup>a</sup>  
Pablo Flores Fernandez<sup>a</sup> Osvaldo Garay Coloma<sup>a</sup>

<sup>a</sup>Critical Care Unit, Carlos Van Buren Hospital, Valparaíso, Chile; <sup>b</sup>Dialysis and Renal Trasplant Unit, Carlos Van Buren Hospital, Valparaíso, Chile

## Keywords

COVID-19 · Acute respiratory distress syndrome · Cytokine release syndrome · Hemadsorption

## Abstract

We present the case of a patient who suffered from acute respiratory distress syndrome caused by pneumonia associated with COVID-19 and cytokine release syndrome. This patient received a high-volume hemofiltration plus adsorption, solving the hemodynamic deterioration, pulmonary infiltrates, and gas exchange. Our clinical case proposes that the extracorporeal therapies can have a role in the management of severe COVID-19.

© 2020 S. Karger AG, Basel

## Introduction

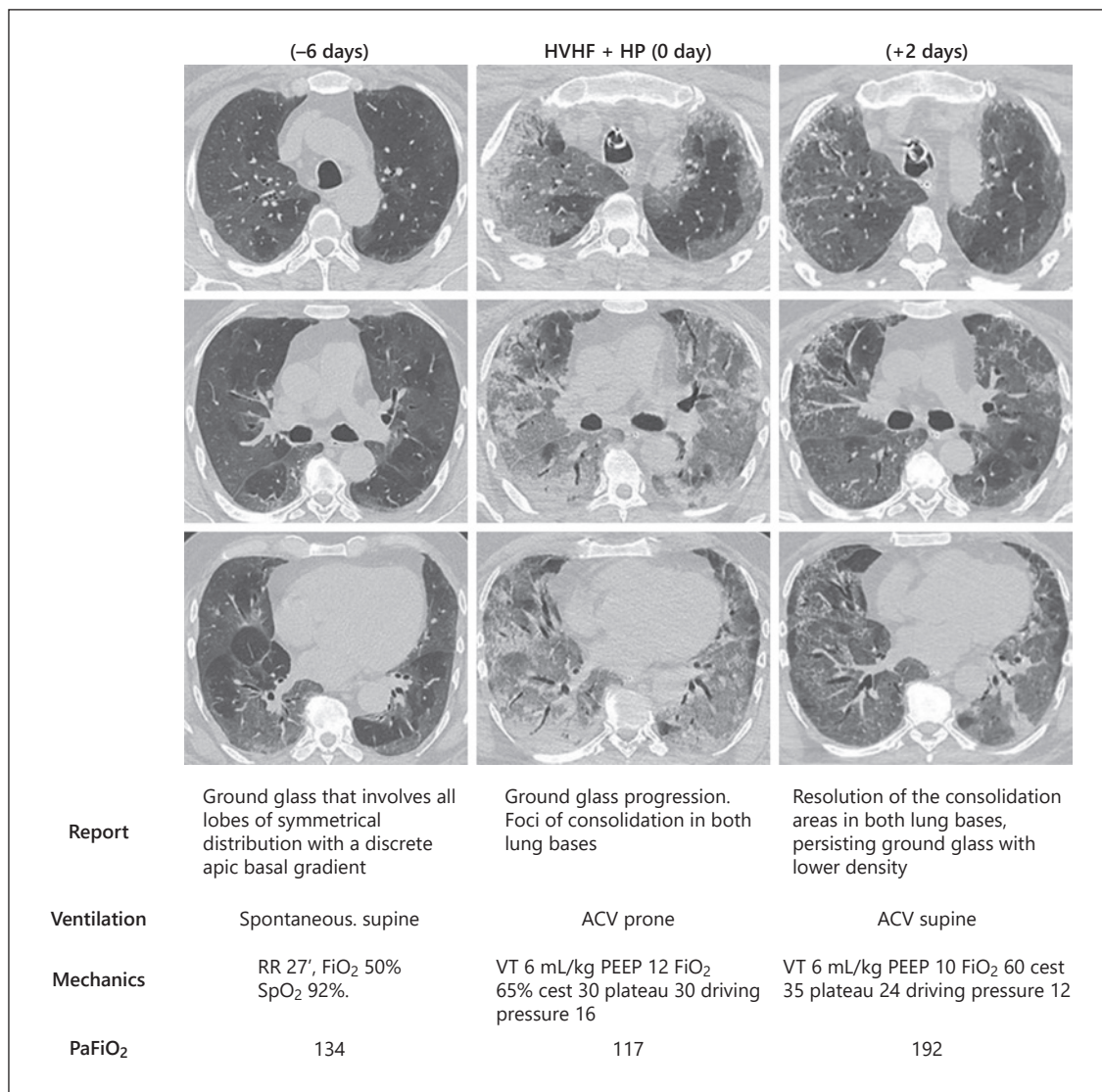
The extracorporeal therapies for COVID-19 have the role of removing the proinflammatory molecules for patients that suffer from severe pulmonary involvement and

cytokine release syndrome (CRS) [1, 2]. Clinical studies in different scenarios and HVHF plus adsorption have shown that its premature use is associated with a decrease of cytokines, improvement of PaO<sub>2</sub>/FiO<sub>2</sub>, better result in severity scores (APACHE II and SOFA), accomplishing the reduction of the sepsis's incidence, days of mechanical ventilation, and mortality [3–5]. Our group proposes that the premature use of extracorporeal therapies for immunomodulation could have a role, modifying the natural history of severe COVID-19.

## Case Presentation

A 59-year-old man presented without comorbidities and 15 days of respiratory symptoms. The chest CT is shown in Figure 1. Upon admission, the data were as follows: PaO<sub>2</sub>/FIO<sub>2</sub> 134, C-reactive protein 132 mg/dL, ferritin 1,278 µg/L, LDH 632 UI/L, and absolute lymphocyte count 376 cel/µL.

He was admitted in the critical care unit, developing gas exchange deterioration (PaFiO<sub>2</sub> 69) requiring mechanical ventilation, recruitment maneuver, neuromuscular blockade, and prone position with improvement of PaO<sub>2</sub>/FIO<sub>2</sub> to 124. The patient develops persistent fever, circulatory instability (noradrenaline 0.14



**Fig. 1.** Imaging of evolution of patient. HP, hemoperfusion.

µg/kg/min), a rise of the inflammatory parameters (C-reactive protein >320 mg/dL, ferritin 2,411 µg/L, and LDH 629 U/L), renal markers (Cr 1.8; [TIMP-2 × IGFβP7] 1.8 (ng/mL)<sup>2</sup>/1,000; severe hyperkalemia 6.6) with a negative microbiological study, deterioration of ventilatory mechanics, and PaO<sub>2</sub>/FiO<sub>2</sub> 114. CT shows a significant progression. Due to the CRS context, HVHF plus adsorption and corticoids therapy was proposed.

A hemoperfusion (HP) of 10 h (HA-380 cartridge, Jafron Biomedical Co.) was performed combined with HVHF in Prismaflex monitor (Baxter) with 250 mL/min blood flow and 70 mL/kg/h effluent dose, with prefilter replacement and heparin. The HP cartridge was installed postfilter. According to local protocol, after 24 h, an 8 h HVHF was performed, maintaining parameters. There were no adverse events associated with the performed process.

Normalization of the temperature and discontinuation of vasoactive drugs during the first hour was accomplished. After that,

we can highlight the significant improvement of the ventilatory mechanics and gas exchange in supine position (PaO<sub>2</sub>/FiO<sub>2</sub> 192) (Fig. 1), without making any changes in the parameters of the mechanical ventilator. Significant regression of CT images was observed. After the described procedure, it was maintained in the intensive unit, evolving with an infection caused by *Enterococcus faecalis*, dying weeks later.

## Discussion and Conclusion

The hemadsorption was proposed as a rescue therapy in a COVID-19 patient with severe ARDS in spite of the protective mechanical ventilation according to the mod-

ern concepts and in which we demonstrated the regression of pulmonary images associated to the improvement in gas exchange and ventilatory mechanics. Unfortunately, it evolves unfavorably due to complications not associated with the procedure.

The CRS and ARDS are phenomena that are related in their pathophysiology, contributing to increase in COVID-19 mortality. Recently a case was reported, in which the intubation's prevention through extracorporeal therapies was achieved [2]. Our team presented this case in which we could avoid the progression of ARDS with HVHF/HP as adjuvant therapy [6].

### Acknowledgements

The authors wish to thank the ICU staff at Carlos Van Buren Hospital.

### Statement of Ethics

Biochemical and clinical parameters were collected under the approval of the scientific Ethics Committee of the health service of Valparaiso – San Antonio. Written informed consent was obtained from the patient's daughter for publication of this case report and any accompanying images. The consent document was authorized and reviewed by the local Ethics Committee.

### References

- 1 Ronco C, Reis T. Kidney involvement in COVID-19 and rationale for extracorporeal therapies. *Nat Rev Nephrol*. 2020;16(6):308–10.
- 2 Vardanjani AE, Ronco C, Rafiei H, Golitaleb M, Pishvaei MH, Mohammadi M. Early hemoperfusion for cytokine removal may contribute to prevention of intubation in patients infected with COVID-19. *Blood Purif*. 2020 Jun 26;1–4.
- 3 You B, Zhang YL, Luo GX, Dang YM, Jiang B, Huang GT, et al. Early application of continuous high-volume haemofiltration can reduce sepsis and improve the prognosis of patients with severe burns. *Crit Care*. 2018;22(1):173.
- 4 Huang Z, Wang SR, Yang ZL, Liu JY. Effect on extrapulmonary sepsis-induced acute lung injury by hemoperfusion with neutral microporous resin column. *Ther Apher Dial*. 2012; 17(4):454–61.
- 5 Tapia P, Chinchón E, Morales D, Stehberg J, Simon F. Effectiveness of short-term 6-hour high-volume hemofiltration during refractory severe septic shock. *J Trauma Acute Care Surg*. 2012;72(5):1228–8.
- 6 Ronco C, Reis T, De Rosa S. Coronavirus epidemic and extracorporeal therapies in intensive care: si vis pacem para bellum. *Blood Purif*. 2020;49(3):255–8.

### Conflict of Interest Statement

The authors report no conflicts of interest. The authors alone are responsible for the content and writing of this article.

### Funding Sources

There was no funding for the study.

### Author Contributions

G.R.G., R.B.H., V.T.C., and F.V.C. designed the work; G.R.G., R.B.H., and F.V.C. collected and analyzed the data; G.R.G., R.B.H., V.T.C., F.V.C., S.R.D., P.F.F., C.L.C., R.O.A., and O.G.C. drafted the work or substantively revised it; and all authors read and approved the final manuscript.

### Availability of Data and Materials

All data generated or analyzed during this study are included in this published article.